



Research Article

Co-infection outbreak of tilapia fish farm associated with severe mortality during summer in Sinaloa, Eastern Pacific: case study

José Ángel Gibrian López-Ceseña¹ , Rosa Stephanie Navarro-Peraza¹ 

Diana Judith López-Peraza¹ , Mario Nieves-Soto¹ 

Gustavo Alejandro Rodríguez-Montes de Oca¹ 

María Amparo Rodríguez-Santiago²  & Mayra I. Grano-Maldonado¹ 

¹Facultad de Ciencias del Mar, Universidad Autónoma de Sinaloa, Mazatlán, México

²Instituto de Ciencias del Mar y Limnología, Estación “El Carmen”

Universidad Nacional Autónoma de México, Ciudad del Carmen Campeche, México

Corresponding author: Mayra I. Grano-Maldonado (granomayra@uas.edu.mx)

ABSTRACT. This study aimed to describe the mass mortality of farmed Nile tilapia (*Oreochromis niloticus*) associated with co-infections during summer in Sinaloa, on the northwest coast of the Mexican Pacific. In July 2023, a parasitic infection occurred at a Nile tilapia farm, coinciding with an increase in water temperature and a decrease in dissolved oxygen, resulting in fish mortality. The fish farmers applied treatments to eliminate the infection and halt the deaths; however, fish continued to die for several days. Thirty moribund fish were collected for laboratory examination and histopathological analysis. The fish showed signs of emaciation, lethargy, and skin abrasions. Parasitological analysis identified ectoparasites, the most abundant of which were peritrichous ciliates on the gills and the host fish's epithelium. Five species were identified: *Trichodina hypsilepis*, *T. magna*, *T. nigra*, *Trichodina* sp., *Ambiphrya* sp., and one unidentified protozoan. The monogeneans *Gyrodactylus cichlidarum* and *Ciclydogyrus* sp. were identified, as well as *Pseudomonas* sp. (probably as a secondary agent). Histopathological examination of the fish gills showed that the protozoan attached to the gill filaments caused severe hyperplasia and gill epitheliocystis. The mortality event lasted 10 days, reaching 50,000 deaths (5,000 dead fish per day). Parasitic infections have significant consequences for farmed fish species and should be considered a fundamental factor in any aquaculture system.

Keywords: ectoparasite; protozoan; bacteria; aquaculture; *Oreochromis niloticus*

INTRODUCTION

Tilapia aquaculture is facing significant challenges related to culture management. Desirable conditions are often difficult to maintain due to environmental variability and inadequate management practices, for example, although considered optimal, pH (6.5-8.5), dissolved oxygen (DO; 3-6 mg L⁻¹), and temperature (27-29°C) are complicated to maintain daily (Hernández-Vidal 2024, Oktami et al. 2024). Feeding strategies, which account for over 50% of operational

costs, require optimization to enhance profitability and sustainability (Hernández-Vidal 2024). Implementing good aquaculture practices, including biosecurity measures and water quality monitoring, is essential to mitigate disease risks and improve fish health (Mastelini & Neto 2024, Palmeira et al. 2024). Addressing these key issues is highly relevant to the ongoing growth of tilapia aquaculture in countries such as Mexico (Hernández-Vidal 2024, Oktami et al. 2024, Palmeira et al. 2024). One significant problem in aquaculture is the presence of parasites, especially ecto-

parasites (Shinn et al. 2023). In this context, ectoparasites are organisms that live on the host's skin or in specific organs such as the gills (Bellay et al. 2015). These parasites can cause central infections in fish, leading to mortality and low productivity in fish farms (Buchmann 2022). Nile tilapia (*Oreochromis niloticus*) is one of the most farmed species worldwide due to its high profitability (FAO 2022). However, like any organism, tilapia hosts a rich fauna of metazoan and protist parasites, many of which have been translocated from Africa with the global movement of tilapia (Abdelaziz & Zaki 2010). Tilapia are susceptible to parasitic infestations, mainly by bacteria, protozoa, and monogenean parasites (Oliveira-Hashimoto et al. 2016, Grano-Maldonado et al. 2018, Haenen et al. 2023, Puicón et al. 2023, Soto-Rodríguez et al. 2024). Monogeneans belong to the Platyhelminthes (flatworms) phylum and parasitize various aquatic organisms (Hutson et al. 2018). They have a direct life cycle with sexual reproduction, which can be oviparous, viviparous, or ovoviviparous (Hoai 2020). Many studies document high infestation and mortality rates, even in tilapia fry (Grano-Maldonado et al. 2018). For instance, records come from Brazil (Jerônimo et al. 2011, Bertaglia et al. 2023), Mexico (Aguirre-Fey et al. 2015), Ethiopia (Beletew et al. 2016), Malaysia (Lim et al. 2016), Saudi Arabia (Suliman & Al-Harbi 2016) and China (Zhang et al. 2019), among others.

The most frequently reported genera of monogeneans in tilapia are *Gyrodactylus* sp. and *Cichlidogyrus* sp. These ectoparasites attach to the skin and gill filaments, causing hyperplasia, hypertrophy, undifferentiated cell proliferation, and interlamellar necrosis, with a preference for warm temperatures (Paredes-Trujillo et al. 2016, 2021, Soler-Jimenez et al. 2017, Grano-Maldonado et al. 2018). Co-infections by both genera have been documented in tilapia (Zago et al. 2014, Yusni & Rambe 2019, Abdel-Latif et al. 2020a,b, López-Ceseña et al. 2024). Research on controlling and eliminating these ectoparasites in fish farms has focused on both natural (Fridman et al. 2014, da Costa et al. 2017, Doan et al. 2020) and chemical treatments (Lima-Boijink et al. 2015, Sandoval-Gio et al. 2019, Zorin et al. 2019, López-Ceseña et al. 2024), yielding promising results. However, infections of this type of ectoparasite continue to be recorded, even in combination with other ectoparasites, such as protozoans (López-Ceseña et al. 2024).

Protozoans are unicellular organisms living in humid or aquatic environments, including fresh and brackish water (Maciel et al. 2018). In fish, they cause white spots on the skin and scales, loss of appetite, and lethargy, causing mortality (Abdel-Baki et al. 2017). One of the protozoans most reported as an infection

agent in aquaculture cultures are trichodinids, even in different aquatic organisms such as Nile tilapia (Valladão et al. 2016, Rodríguez-Santiago et al. 2019, Attia et al. 2021), eel (*Anguilla anguilla*) (Madsen et al. 2000), pike perch (*Sander lucioperca*) (Naas et al. 2024), goldfish (*Carassius auratus*) (Mandira et al. 2017), banded knife fish (*Gymnotus carapo*) (Sousa-Filho et al. 2021), and salmonids (Mizuno et al. 2016), among others. Trichodinids are ectoparasites that live on the skin and gills, causing cellular damage (Rodríguez-Santiago et al. 2019, Rivas-Beltrán et al. 2023). Co-infections of trichodinids and monogeneans have been reported in aquaculture cultures, causing severe damage and significant economic losses due to high mortality rates (Aly et al. 2020, Anshary et al. 2023). Other ciliates, such as *Apiosoma* spp. (Sessilida), are peritrich ciliates with a scopula as a substrate-attaching organ. These peritrichs primarily live on the gills and body surfaces of aquatic organisms, causing significant losses in aquaculture (Li et al. 2016).

Another group of unicellular organisms is bacteria, which have been reported to cause mortality in aquaculture cultures (Chatterjee & Haldar 2012). Bacteria cause infection when the fish is under stress, injured, or infected by another pathogen, which depresses the immune system and allows the bacteria to pass to the host (Austin 2019, Soto-Rodríguez et al. 2024). Among the most common genera that cause bacterial diseases in fish are *Flavobacterium* sp. (Loch & Faisal 2015, Wahli & Madsen 2018), *Aeromonas* sp. (Duman et al. 2018, Pareira et al. 2022), *Streptococcus* sp. (Ortega et al. 2018, Young et al. 2020, Phuoc et al. 2021), and *Pseudomonas* sp. (Wiklund 2016, Kačániová et al. 2017). Environmental conditions known to favor the development of parasitic infections include temperature, as metabolism accelerates and, consequently, life cycles, making the infection more easily transmitted (Paull et al. 2015), as reported in Sinaloa for the monogenean *Gyrodactylus cichlidarum* (Grano-Maldonado et al. 2018). Although ectoparasite infections have been previously documented in fish, the co-occurrence of pathogens in this region remains underexplored. In this context, the present study aimed to identify the ectoparasites present on cultured *O. niloticus* at the morphological level and to evaluate the damage caused by co-infections through histological analysis.

MATERIALS AND METHODS

Tilapia rearing conditions

In early May 2023, 55,000 Nile tilapia (0.5 ± 0.1 g) that had undergone sex reversal were stocked. Thirty-five

thousand fish from the initial stock (55,000) were stocked in a 1,200 m³ earthen pond, and the remaining 20,000 were stocked in 16 square concrete tanks of 65 m³ at a density of 1,250 fish per tank. The farm is located 18 km south of Mazatlán, Sinaloa state, on the Pacific coast (23°14'23.93"N, 106°15'37.88"W). Nile tilapias were intended to be reared for seven months and harvested from late October to mid-November. The total expected production at the fish farm is 35,000 to 45,000 fish per cycle (40 mt per year). Fish were fed daily with locally available commercial feeds at a weekly adjusted feeding ratio. All tanks had constant aeration (4 HP paddle-wheel aerators in the earth pond) and 2 HP blowers per 4 concrete tanks (0.5 HP per unit with 10 m of Aerotube©), with daily water renewal of 10-20%. Several water quality parameters were monitored using a YSI PRO-20 oximeter for DO and temperature, an API ammonia (NH⁻³/NH⁺⁴) test kit colorimeter kit for total ammonia-nitrogen (TAN), and an API pH test kit throughout the rearing period.

Fish mortalities

No Nile tilapia mortalities were observed at the facilities during their initial maintenance or growth-out period until July 2023. Many tilapias began to die shortly after the water temperature increased from 32 to 35°C, and DO levels were below 2 mg L⁻¹ in late July and early August. In the first week, approximately 10,000-15,000 fish died. The fish farm personnel first employed a series of oxytetracycline (antibiotic treatments; 20 mg kg⁻¹ commercial feed) for five days. Thereafter, 1 h consecutive immersion baths of both salt (2.5-3 g L⁻¹) and formaldehyde (100 mg L⁻¹) treatments with constant aeration (~0.5 HP per 65 m³ tank and water exchange (100-200 L min⁻¹) to flush the tanks from day 3-10 upon first signs of mortality. Despite these medication interventions, the treatment administration did not reduce the fish mortality rate on the first day. Since the infection was detected, a total of 44,000 to 50,000 fish have been lost over the next 3 to 10 days, representing 80-90% of the fish farm's entire stock. It's worth noting that the medication treatments did not affect the water chemistry parameters, suggesting the issue may be more complex than initially thought. Upon arrival at the fish farm, macroscopic examination of ~10 fish *in situ* revealed monogeneans and protozoans on the skin.

Sample collection

On day 3, following the antibiotic treatment and the subsequent mass mortality, a comprehensive sample collection process was initiated. A random sample of 30 fish was carefully transported to the laboratory for

evaluation. Samples from the body mucus (skin) and gills were individually collected through scraping with the aid of glass slides (or removing the organ) and examined for parasites under a stereomicroscope (Velab®) and an optical microscope (Leica DM5000). Ten dead fish were fixed in 10% formalin and evaluated in the laboratory CA-UAS-162 at the Facultad de Ciencias del Mar.

Parasitological and bacteriological analysis

Each fish underwent a meticulous examination using a stereomicroscope. Monogeneans attached to the external surfaces were counted and carefully removed using needles (size 16, Barber of Sheffield, UK) as described by Grano-Maldonado et al. (2018) and López-Ceseña et al. (2024). The remaining fish's skin, gills, and mouth cavities were thoroughly examined for ectoparasites under an Olympus SZ30 stereomicroscope. Ten monogeneans were prepared as whole mounts using a square 18×18 mm "0" thickness (VWR International®) coverslip and sealed with commercial nail varnish. The haptor armature and copulatory complex were studied using an immersion oil objective on a Leica DMLB 10 compound microscope, as described by Grano-Maldonado et al. (2018). Images of the ectoparasites were captured using a Sony CCD Iris camera mounted on a compound microscope with a 40x or 100x oil-immersion lens. Each specimen was subjected to morphometric analysis of the attachment hooks following the methods described by Grano-Maldonado et al. (2018). Skin and gill samples were taken from each fish under aseptic conditions, inoculated onto TSA agar and cetrimide agar (Dibico®), and incubated (Fisher Scientific) at 37°C for 48 h. Bacterial colonies were examined under UV light and identified by Gram staining before being examined under a light microscope (Leica DM5000) to describe their morphology. Protozoa were observed under a Leica microscope for taxonomic identification, revealing the presence of trichodinids. For confirmation, the samples were dried at room temperature for subsequent staining. Klein silver staining was used to observe denticle structures, insertion disc characteristics, and the number of their constituents. Peritrichous ciliates, an unidentified protozoan, and Trichodinids were counted using a 10x objective. The average value across five fields was classified as very low (<1), low (1-5), moderate (6-50), high (51-100), or very high (100+), following Bunkley-Williams & Williams Jr. (1995).

Additionally, Harris hematoxylin staining was used to observe the nuclear apparatus as supplementary

information, as described by Lom (1958) and Wellborn (1967). The Klein technique was used to mount the stained slides. These were examined in detail under a microscope for trichodinids. Fully mature, well-formed trichodinids with all components of the adhesive disc clearly visible and well-stained were selected. At 1,000x magnification, details of the denticle morphology of each organism, lamina, and ray, the degree of silver impregnation of the center of the adhesive disc, and the presence or absence of chitinous structures, etc., were observed. The angle of the adoral whorl was also noted. To identify these characteristics taxonomically, they were initially compared with the descriptions of Lom & Dyková (1992). Subsequently, a comprehensive review of original studies was conducted to determine the species, which involved taking the necessary measurements. Finally, prevalence and average intensity values were obtained using the following equation: prevalence (P) = infected fish / total fish examined \times 100, mean intensity (MI) = total number of parasites of one species / number of infected fish (Bush et al. 1997).

Histological analysis

Gills from 10 fish were fixed in an alcoholic Bouin solution for 24 h and subsequently dehydrated in ascending concentrations of ethyl alcohol, cleared in xylene, and embedded in paraffin wax. Transverse sections were cut at 5 μ m and stained with hematoxylin and eosin (H&E) following Grano-Maldonado et al. (2018). This comprehensive histological analysis was conducted to provide a detailed understanding of the fish's internal conditions. Finally, the slides were examined and photographed under a light microscope (Olympus) equipped with a camera.

Ethical procedures

The experiment was conducted in accordance with the standards of Mexican law on methods for the humane slaughter of animals, specifically NOM 033-ZOO-1995 and NOM-062-ZOO-1999, which establish the proper use and handling of animals in the laboratory.

RESULTS

Physicochemical parameters

During the mortality outbreak the present values were as follows: temperature ($27.8 \pm 1.5^\circ\text{C}$), pH 7.2 ± 0.3 and DO for the entire rearing period was 3.2-5.7 mg L⁻¹, TAN 0.5-2.8 mg L⁻¹ for the earthen pond, and tempera-

ture ($29.7 \pm 2.4^\circ\text{C}$), pH 7.8 ± 0.5 , DO 1.4-4.6 mg L⁻¹ and TAN 0.5-2.8 mg L⁻¹ as mean values for concrete tanks.

Macroscopic examination

Each fish (n = 30) (Fig. 1) was found to be parasitized by two monogenean species: *G. cichlidarum* (P = 100%, MI = 41) on the skin, gills, and mouth, and *Ciclidogyrus* sp. (P = 100%, MI = 20) on the gills (Fig. 2). This was determined through macroscopic examination process, which involved detailed visual inspection of the fish's external and internal surfaces to identify any visible parasites or abnormalities.

The main morphological characters used to identify this species of monogenean were based on morphometric features of the complex parts of *Gyrodactylus* spp. collected in the present study, which were very similar to those of *G. cichlidarum* (according to Grano-Maldonado et al. 2018) and *Tricodina* spp. (Rodríguez-Santiago et al. 2019, 2021). The measurements obtained from farmed Nile tilapia in this study align well with those reported by Grano-Maldonado et al. (2018). Additionally, we identified *Pseudomonas* species colonies as coinfecting agents in fish, isolated from skin and gill samples, cultured on cetrimide agar. The identification was confirmed by microscopy (Fig. 3), revealing Gram-negative, rod-shaped bacteria.

Histological examination

The histological examination of the infected gills in farmed Nile tilapia reveals significant alterations, including swelling of both the primary and secondary lamellae, accompanied by hyperplasia attributed to epitheliocystis (Fig. 4). The examination revealed a considerable presence of undifferentiated proliferating cells, along with hypertrophy, and inter-lamellar necrosis attributed to the protozoan *Ambiphrya* sp. (Fig. 5). *In vivo* photographs showed a high density of protozoan (51-100 ind) in lamellae. This detail became less apparent after fixation.

The presence of co-infection in the gills, including the monogenean *Ciclidogyrus* and *Ambiphrya* sp. along with *G. cichlidarum*, *Trichodina hypsilepis* Wellborn (note: this species, frequently recorded for teleost hosts as *T. heterodontata*, was recently synonymized by de Jager & Basson (2019)), *T. magna* Van As & Basson, 1989, *T. nigra* Lom, 1960, *Tricodina* sp. (Fig. 6), as well as an unidentified ciliated protozoan on the skin (Fig. 7), suggests a complex interaction among multiple pathogens.



Figure 1. a) Nile tilapia *Oreochromis niloticus* in Sinaloa, eastern Pacific, b) skin abrasion in the caudal fin, notice the redness on the skin, c-d) pectoral fin, observe the inflammation (redness) on the base of the fin (arrowhead).

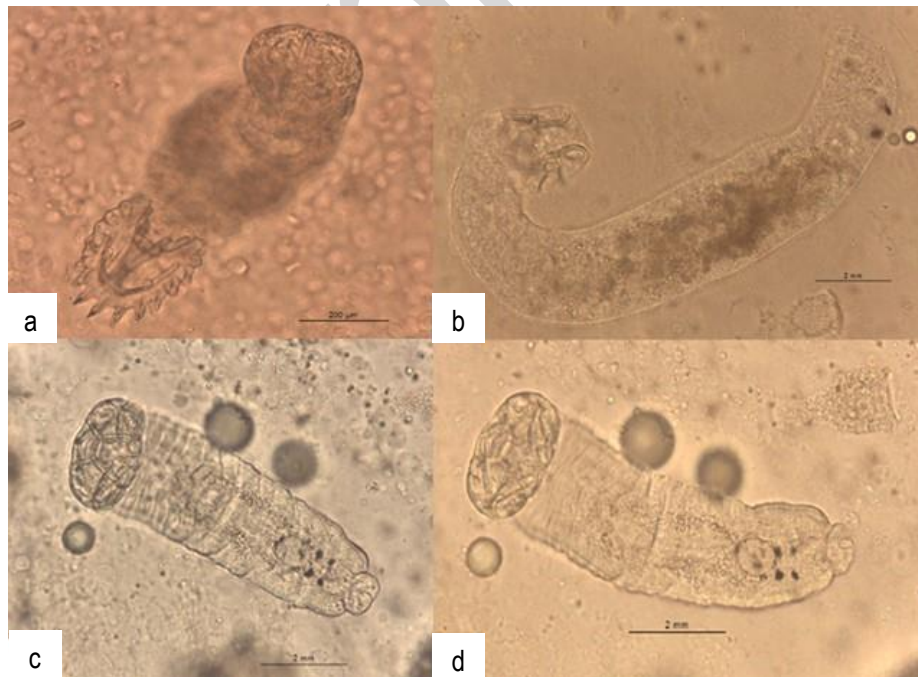

Figure 2. Skin and gill smear samples. a) *Gyrodactylus cichlidarum* Paperna, 1968 (Monogenea: Gyrodactylidae). Scale bar (200 μm); b-d) *Cichlidogyrus* sp. Paperna, 1960, on the gills of *O. niloticus* from Sinaloa, Mexico. Scale bar (100 μm).

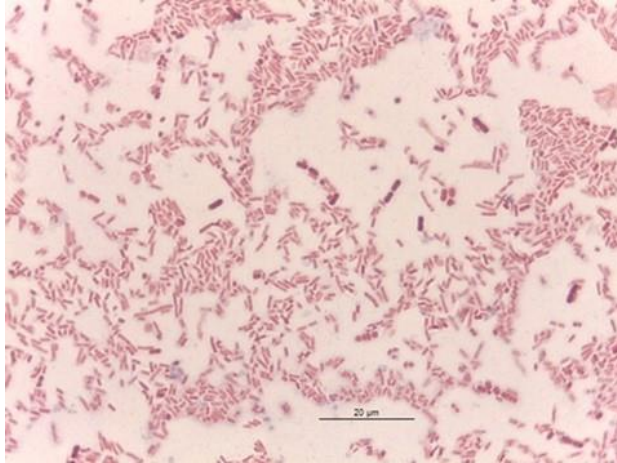


Figure 3. *Pseudomonas* spp. species infection in cultured Nile tilapia (*Oreochromis niloticus*). *Bacillus* is a Gram-negative bacterium that is red-pink in color and is distributed in aquatic environments. Scale bar (20 μm).

DISCUSSION

This study of Nile tilapia samples from aquaculture facilities along Mexico's Pacific coast identified co-infections involving protozoans, monogeneans, and bacteria that could lead to significant fish mortality. To prevent disease and economic loss, tilapia aquaculture must consider the impact of physical stressors on fish health. Mastelini & Neto (2024) highlighted that water management and quality influence pathogen outbreaks, with management practices responsible for 34% of bacterial outbreaks, water quality for 38% of bacterial outbreaks, and 16.2% of metazoan-related outbreaks. Key parameters linked to infections include temperature above 30°C, dissolved oxygen below 5.5 mg L⁻¹, pH below 8.0, and ammonia above 1.0 mg L⁻¹, though their statistical significance was under 20%. Primary risk factors are high temperatures (30-35°C), low DO (<5 mg L⁻¹), and high ammonia (1-5 mg L⁻¹). Temperature affects ectothermic organisms by altering metabolic rate and parasite biology, including growth and reproduction (Hirazawa et al. 2010, Swingle et al. 2013). Our findings show that 35°C supports pathogenic development. As temperatures rise, parasites tend to produce more eggs, indicating better adaptability (Paull et al. 2015). This trend is observed in monogeneans such as *Dactylogyrus extensus*, which exhibit increased egg hatching and larval development at 25°C but are inhibited at 2-3°C (Turgut 2012). Similarly, *Neobenedenia* sp. hatches more successfully at higher temperatures, reaching maturity in 7 days at 30°C, and individuals are larger at that temperature than

at 20 or 25°C. Egg hatching at 30°C takes about 13 days, whereas it takes only 6 days at 30°C (Hirazawa et al. 2010). Higher infection rates of *Cichlidogyrus* sp. are observed during warmer periods (Aguirre-Fey et al. 2015). Overall, elevated temperatures combined with low oxygen levels significantly increase the risk of parasitic infections, thereby increasing mortality in commercially valuable fish.

Identifying *Trichodina* species is essential because they can negatively impact fish aquaculture, such as tilapia (Valladão et al. 2016). While these parasites might not directly cause mortality, they can cause subclinical damage that exacerbates disease caused by other stressors (Shinn et al. 2023). Species such as *T. hypsilepis*, *T. magna*, *T. nigra*, and *T. centrostrigata* can cause notable tissue alterations, including hypertrophy, hyperplasia, and lamellae fusion. These changes can result in asphyxia, feeding difficulties, irregular swimming, and weakened immune responses (Rodríguez-Santiago et al. 2021). Trichodinids display a variety of morphological traits; some species may have limited known hosts. Most research in Mexico has mainly documented *Trichodina* sp. infections across various fish species, with scant data on other trichodinids. Findings from this study indicate that multiple trichodinid species already exist in the wild and may also be present in aquaculture environments. Hence, the risk of trichodinid infections is not limited to the *Trichodina* genus; it may involve other trichodinids. Co-infections involving ectoparasites should be considered a significant concern in fish farming (Shinn et al. 2023). Various methods, including natural approaches, are available to remove parasites from aquaculture systems. Natural methods include the use of salt (García-Magaña et al. 2019, Araújo et al. 2023) and plant-based treatments (da Costa et al. 2017, Doan et al. 2020). Chemical options primarily include formalin (Grano-Maldonado et al. 2018, Tancredo et al. 2019) and trichlorfon (Zhang et al. 2014, Araujo et al. 2023). Although effective, these chemicals pose risks of toxicity to aquatic animals (Tavares-Días 2021). More gentle alternatives, such as Dermo Gard® Aqua, a skin protectant with expectorant properties, are recommended for the elimination of ectoparasites, including monogeneans (Enríquez-Benavides et al. 2025). It has shown success in species like *O. niloticus* (López-Ceseña et al. 2024) and *Cyprinus carpio* (Van et al. 2021). Nonetheless, further research is necessary to develop more effective control methods and to ensure fish health, as parasitic infections can occur at any time.

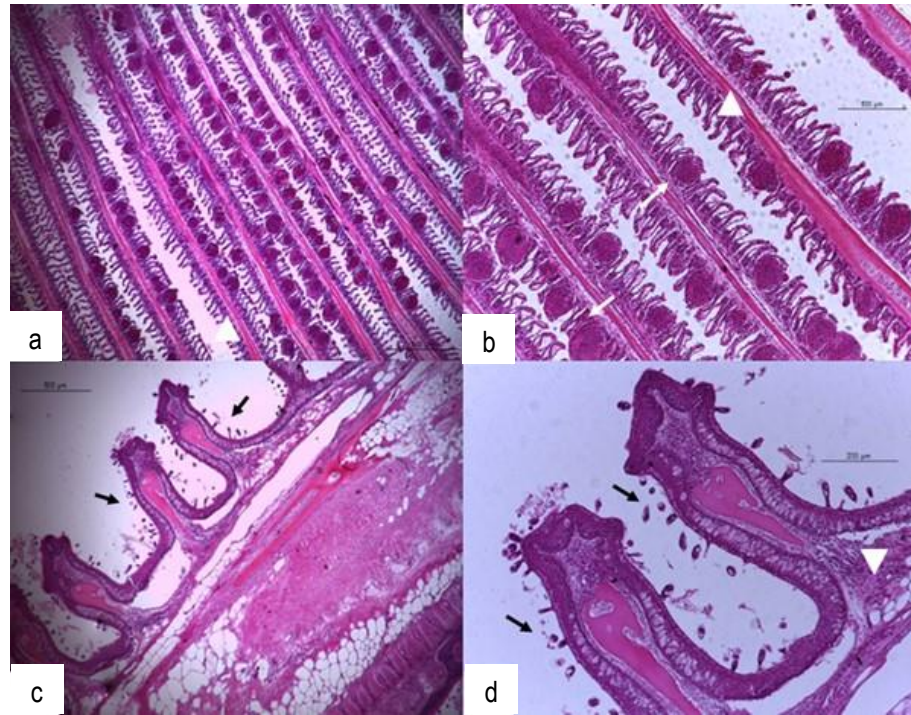


Figure 4. Gill's histological samples. a) Severe histopathological lesions of gills from farmed Nile tilapia (*Oreochromis niloticus*) infected with *Ambiphrya* sp. Raabe, 1952 (white arrowhead), b) notice the damage caused by inflammation on the gill filaments (white arrow), c) *Ambiphrya* sp. covering the gill lamella (black arrow), d) primary and secondary lamellae apex swelling with hyperplasia caused by *Ambiphrya* sp. (black arrow). Note the presence of many undifferentiated proliferating cells, hypertrophy, and interlamellar necrosis (white arrowhead). a,c) scale bar (500 μ m), b,d) scale bar (200 μ m).

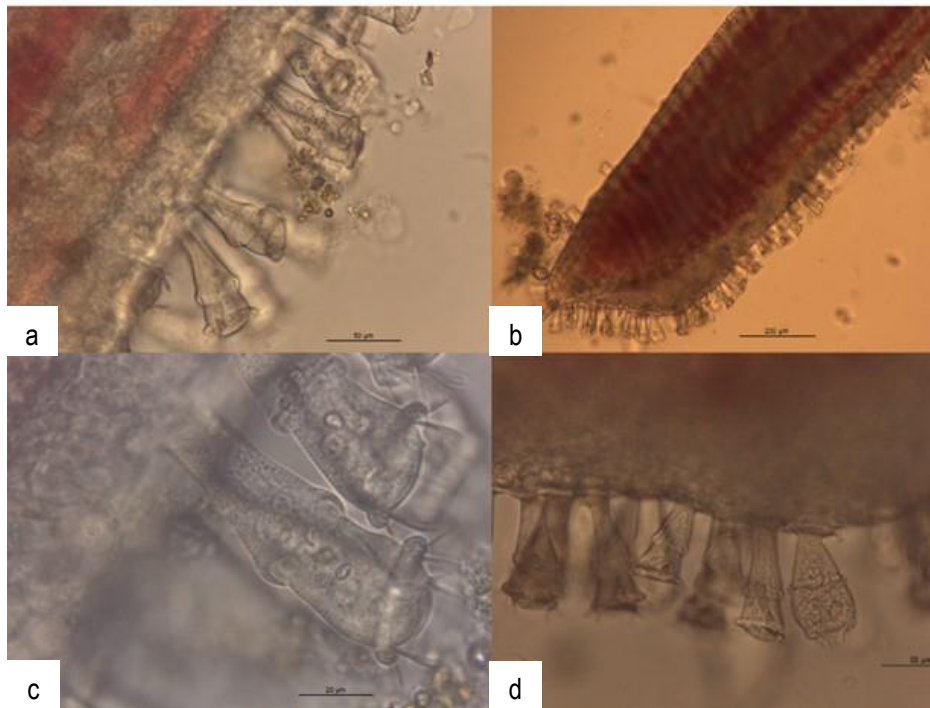


Figure 5. Gill fresh samples. *Ambiphrya* sp. Raabe, 1952. A group of peritrichous ciliates covering the gill epithelium of cultured Nile tilapia. a) 10x, b) 4x, c) 40x, d) 10x.




Figure 6. Ciliophora. a) Trichodinids of the gill arches and b) skin of Nile tilapia (*Oreochromis niloticus*) in a differential interference contrast microscope. Microphotograph of the adhesive disc of *Trichodina* in silver nitrate impregnation, c) *T. hypsilepis*, d) *T. magna*, e) *T. nigra*, f) *Trichodina* sp. Scale bars: a-b = 50 µm; c-f = 20 µm.

Monogeneans infecting Nile tilapia are probably the most widespread parasites in tropical freshwater fish. Shinn et al. (2023) noted that Mexico has introduced 40 helminth species and imported fish, of which 33 are monogeneans, including 14 species associated explicitly with tilapia. *Trichodina*, a common and diverse protozoan parasite, includes over 300 species (Tang et al. 2013, Valladão et al. 2016, Shinn et al. 2023). In Mexico, 18 trichodinid species have been recorded mainly on the skin and gills of different fish species (Aguilar-Aguilar & Islas-Ortega 2015). These parasites are prevalent in aquaculture settings, where they cause severe tissue damage, including hypertrophy, hyperplasia, and lamellae fusion. Such damage can result in asphyxiation, feeding issues, and abnormal swimming in infected fish (Rodríguez-Santiago et al. 2019, Khallaf et al. 2020). Protozoa such as *Ambiphrya* spp. and *Apiosoma* spp., also reported in tilapia (Pantoja et al. 2012), have spread globally as ectoparasites. These organisms can cause significant

tissue pathology in infected fish (Steckert et al. 2018). Temperature was found to be a key factor promoting the growth of parasites and pathogens (Suliman et al. 2016), exceeding ammonium levels as the primary influence on the abundance of the monogenean *Cichlidogyrus* spp. in Yucatán, Mexico (Paredes-Trujillo et al. 2016, 2021). In this study, approximately 55,000 tilapias were lost over 20 days, with mortality reaching 80-90% of the initial stock due to co-infection. Fish farmers are advised to use salt bath treatments with 30 g L⁻¹ of sodium chloride for 10 min, which significantly reduces parasites in captive tilapia (García-Magaña et al. 2019). Although current infection levels of the monogeneans *G. cichlidarum* and *Cichlidogyrus* are low, fish managers should remain alert for these parasites. Early detection is vital, especially for *G. cichlidarum*, which caused high mortality in juvenile tilapia (Grano-Maldonado et al. 2018).

To date, 31 *Aeromonas* spp. infections have been reported; these Gram-negative bacteria are common in aquatic environments and can act as opportunistic pathogens in fish and other marine organisms (Algammal et al. 2020). They infect hosts through virulence factors that enable colonization and invasion, and stress conditions increase the risk of infection in fish (Gonçalves-Pessoa et al. 2020). Human infections, mainly in immunocompromised individuals, are associated with *A. hydrophila*, *A. veronii*, and *A. schubertii* (Fernández-Bravo et al. 2020). However, in our study, no *Aeromonas* was detected; instead, *Pseudomonas* sp. was identified on both skin and gills. Several *Pseudomonas* species cause septicemic diseases in various fish species. For example, Álcantara-Jauregui et al. (2022) reported that these bacteria cause "red spot disease" in rainbow trout (*Oncorhynchus mykiss*) and tench (*Tinca tinca*). They noted that in rainbow trout, infection can lead to sudden mortality, with mortality rates reaching 100% regardless of season or temperature.

Symptoms include skin darkening, hemorrhages, and ulcerations that can extend to fins and tail, consistent with lesions seen in *O. niloticus* in this study. Any bacteria present can threaten aquaculture health and potentially spread within shared water supplies (Soto-Rodríguez et al. 2024). Ectoparasites such as trichodinids and monogeneans are common in Mexican tilapia farms, and infection severity is influenced by factors including poor fish health, mortality, and economic losses, as observed in a Sinaloa fish farm. Warm summer temperatures in Sinaloa promote the development of parasitic organisms. Most mortalities

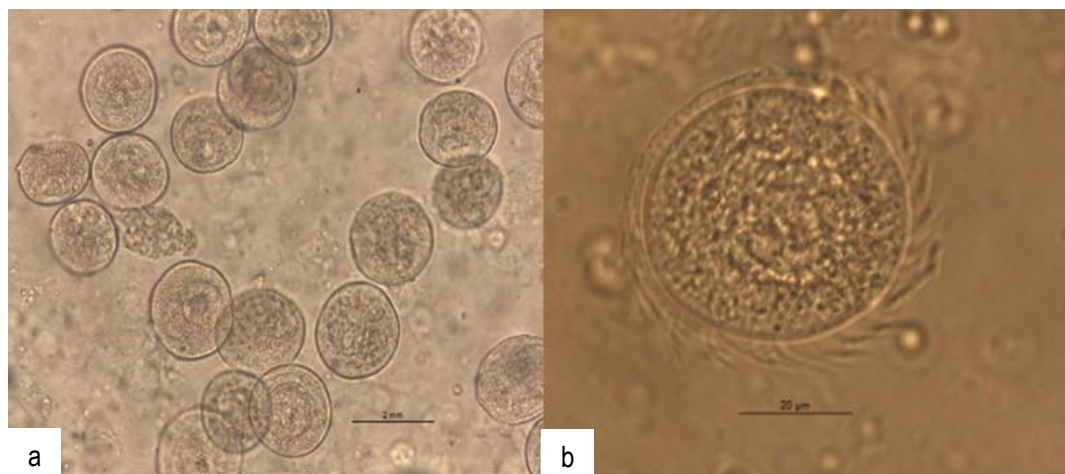


Figure 7. An unidentified ciliated protozoan from the skin of Nile tilapia (*Oreochromis niloticus*).

occur during fry male reversal (Grano-Maldonado et al. 2018) and in Veracruz (Jiménez-García et al. 2020), suggesting this period is critical for enhanced sanitization protocols, especially in summer (Suliman et al. 2016). These findings highlight the need for standardized sampling during the reversal period, including constant monitoring of abiotic factors and smear tests to detect ectoparasites early and better understand host-parasite interactions. Our goal is to improve prevention and control strategies for ectoparasites in tilapia farming to reduce economic losses. However, we recognized some limitations of this study: i) we focused on moribund fish, which means the sample may not accurately reflect the early stages of infection or the fish that survived, potentially leading to an overestimation of lesion severity or co-infection; ii) environmental factors: the highest mortality coincided with an increase in water temperature and a decrease in dissolved oxygen, while co-infections (monogeneans, protozoan parasites and *Pseudomonas* sp.) are identified as the likely cause, maybe the extent to which environmental stressors alone contributed to the mortality and also this is case of report and the extension of the infection may not be fully determined without a controlled experimental design; and, iii) fish farmers treated previously to eliminate the infection and the fish mortality. The study provides a detailed description of the pathology and associated pathogens during the event. Still, its limitations are mostly from being a descriptive case study (an epizootiological description) rather than a controlled experiment. This type of study is excellent for generating hypotheses but is limited in its ability to

definitively prove causality or generalize the findings to other situations.

CONCLUSIONS

This finding suggests that fish mortality may result from a combination of factors, including parasitic and bacterial co-infections, which require further investigation. These infections might also stem from earlier stressors such as elevated temperatures in the northwest Pacific, low oxygen levels, and drug treatments. Continuous monitoring of fish farm tanks and implementing measures to prevent such events, like increasing water flow, enhancing water exchange, and adding extra oxygen pumps during both day and night, as well as regular examination of some fish under the microscope to identify possible monogeneans and protozoa, is essential to prevent mortality events during the summer.

Credit the author's contribution

J.Á.G. López-Ceseña: validation, conceptualization, writing of the original manuscript, data analysis, photographic editing and sample processing; R.S. Navarro-Peraza: data analysis, review, editing and sample processing; D. López-Peraza: review and editing; M. Nieves-Soto: review and editing; G.A. Rodríguez-Montes de Oca: obtaining biological material, review and editing; M.A. Rodríguez-Santiago: sample processing, photographic editing, review and editing; M.I. Grano-Maldonado: sample processing, obtaining biological material, methodology, funding, review and editing. All authors have

read and accepted the published version of the manuscript.

Conflict of interest

The authors and the fish farm declare no conflict of interest.

ACKNOWLEDGEMENTS

J.Á.G. López-Ceseña, thanks to Secretaría de Ciencia, Humanidades, Tecnología e Innovación (SECIHTI) for the scholarship (CVU 1233531). The authors would like to thank the personnel at the fish farm for all their invaluable assistance in collecting and providing samples. We also extend our thanks to the social services students assigned to the project "Identification of pathogens and parasites in aquatic organisms of the coastal area of Sinaloa": Elizabeth Hernández Flores, Sandra Lizeth Pérez Vallejo, and Edén Alejandro Rodríguez Vázquez, who helped during sampling. Thanks to anonymous reviewers for their constructive feedback, which significantly improved the manuscript.

REFERENCES

- Abdel-Baki, A.A.S., Al Ghamdi, A. & Al-Quraishy, S. 2017. First record of three African trichodinids (Ciliophora: Peritrichida) in cultured Nile tilapia (*Oreochromis niloticus*) in Saudi Arabia with re-evaluation of their host specificity. *Parasitology Research*, 116: 1285-1291. doi: 10.1007/s00436-017-5407-0
- Abdel-Latif, H.M.R. & Khafaga, A.F. 2020. Natural co-infection of cultured Nile tilapia *Oreochromis niloticus* with *Aeromonas hydrophila* and *Gyrodactylus cichlidarum* experiencing high mortality during summer. *Aquaculture Research*, 51: 1880-1892. doi: 10.1111/are.14538
- Abdel-Latif, H.M.R., Dawood, M.A., Menanteau-Ledouble, S., et al. 2020. The nature and consequences of co-infections in tilapia: A review. *Journal of Fish Diseases*, 43: 651-664. doi: 10.1111/jfd.13164
- Abdelaziz, M.A. & Zaki, M.M. 2010. Investigation of mass mortality problem of *Oreochromis niloticus* in Mariotia channel in Egypt. *World Journal of Fish and Marine Sciences*, 2: 461-470.
- Aguilar-Aguilar, R. & Islas-Ortega, A.G. 2015. A checklist of ciliate parasites (Ciliophora) of fishes from Mexico. *Zootaxa*, 4027: 270-280. doi: 10.11646/zootaxa.4027.2.6
- Aguirre-Fey, D., Benítez-Villa, G.E., de León, G.P.P., et al. 2015. Population dynamics of *Cichlidogyrus* spp. and *Scutogyrus* sp. (Monogenea) infecting farmed tilapia in Veracruz, Mexico. *Aquaculture*, 443: 11-15. doi: 10.1016/j.aquaculture.2015.03.004
- Alcántara-Jauregui, F.M., Valladares-Carranza, B. & Ortega, S.C. 2022. Enfermedades bacterianas y sus agentes etiológicos identificados en peces de México. *Revista MVZ Córdoba*, 27: e2387. doi: 10.21897/rmvz.2387
- Algammal, A.M., Mohamed, M.F., Tawfik, B.A., et al. 2020. Molecular typing, antibiogram and PCR-RFLP-based detection of *Aeromonas hydrophila* complex isolated from *Oreochromis niloticus*. *Pathogens*, 9: 238. doi: 10.3390/pathogens9030238
- Aly, S., Fathi, M., Youssef, E.M., et al. 2020. Trichodinids and monogeneans infestation among Nile tilapia hatcheries in Egypt: prevalence, therapeutic and prophylactic treatments. *Aquaculture International*, 28: 1459-1471. doi: 10.1007/s10499-020-00537-w
- Anshary, H., Sriwulan, S. & Amriana, A. 2023. High prevalence and mean intensity of trichodinids and monogeneans on Nile tilapia (*Oreochromis niloticus*) in Indonesian hatcheries. *Veterinary Parasitology: Regional Studies and Reports*, 43: 100898. doi: 10.1016/j.vprsr.2023.100898
- Araújo, P.A., Maciel-Honda, P.O., de Oliveira-Costa-Fernandes, T., et al. 2023. Efficacy of chlorine, sodium chloride, and trichlorfon baths against monogenean *Dawestrema cycloancistrum* parasite of pirarucu *Arapaima gigas*. *Journal of Fish Diseases*, 46: 113-126. doi: 10.1111/jfd.13725
- Attia, M.M., Elgendy, M.Y., Prince, A., et al. 2021. Morphomolecular identification of two trichodinid co-infections (Ciliophora: Trichodinidae) and their immunological impacts on farmed Nile Tilapia. *Aquaculture Research*, 52: 4425-4433. doi: 10.1111/are.15281
- Austin, B. 2019. Methods for the diagnosis of bacterial fish diseases. *Marine Life Science & Technology*, 1: 41-49. doi: 10.1007/s42995-019-00002-5
- Beletew, M., Getahun, A. & Vanhove, M.P. 2016. First report of monogenean flatworms from Lake Tana, Ethiopia: gill parasites of the commercially important *Clarias gariepinus* (Teleostei: Clariidae) and *Oreochromis niloticus* tana (Teleostei: Cichlidae). *Parasites & Vectors*, 9: 1-7. doi: 10.1186/s13071-016-1691-2
- Bellay, S., De Oliveira, E.F., Almeida-Neto, M., et al. 2015. Ectoparasites and endoparasites of fish form networks with different structures. *Parasitology*, 142: 901-909. doi: 10.1017/S0031182015000128

- Bertaglia, E.D.A., Furtado, W.E., Silva-Souza, A.T., et al. 2023. Influence of seasonality and culture stage of farmed Nile tilapia (*Oreochromis niloticus*) with monogenean parasitic infection. *Animals*, 13: 1525. doi: 10.3390/ani13091525
- Buchmann, K. 2022. Control of parasitic diseases in aquaculture. *Parasitology*, 149: 1985-1997. doi: 10.1017/S0031182022001093
- Bunkley-Williams, L. & Williams, E.H. 1995. Parásitos de peces de valor recreativo en agua dulce de Puerto Rico. Proyecto de Enfermedades de Peces de Valor Recreativo. Universidad de Puerto Rico, San Juan.
- Bush, A.O., Lafferty, K.D., Lotz, J.M., et al. 1997. Parasitology meets ecology on its own terms: Margolis et al. revisited. *Journal of Parasitology*, 575-583. doi: 10.2307/3284227
- Chatterjee, S.H.A. & Haldar, S. 2012. *Vibrio*-related diseases in aquaculture and development of rapid and accurate identification methods. *Journal of Marine Science: Research & Development*, 1: 1-7. doi: 10.4172/2155-9910.S1-002
- da Costa, J.C., Valladão, G.M.R., Pala, G., et al. 2017. *Copaifera duckei oleoresin* as a novel alternative for treatment of monogenean infections in pacu *Piaractus mesopotamicus*. *Aquaculture*, 471: 72-79. doi: 10.1016/j.aquaculture.2016.11.041
- de Jager, G.P. & Basson, L. 2019. Taxonomic assessment of three North American trichodinids by reevaluating the taxon validity of *Trichodina heterodontata* Duncan, 1977 (Peritrichia). *Acta Protozoologica*, 58: 125-139. doi: 10.4467/16890027AP.19.013.11914
- Doan, H.V., Soltani, E., Ingelbrecht, J., et al. 2020. Medicinal herbs and plants: Potential treatment of monogenean infections in fish. *Reviews in Fisheries Science & Aquaculture*, 28: 260-282. doi: 10.1080/23308249.2020.1712325
- Duman, M., Saticioglu, I.B., Janda, J.M., et al. 2018. Determining the infectious status and prevalence of motile *Aeromonas* species isolated from disease cases in rainbow trout (*Oncorhynchus mykiss*) and aquarium fish. *Journal of Fish Diseases*, 41: 1843-1857. doi: 10.1111/jfd.12896
- Enríquez-Benavides, L., López-Ceseña, J., Rodríguez-Montes de Oca, G., et al. 2025. Effective control and treatment of *Rhabdosynochus viridisi* (Monogenea: Diplectanidae) in *Centropomus viridis* (Teleostei: Centropomidae) in marine aquaculture. *Latin American Journal of Aquatic Research*, 53: 375-387. doi: 10.3856/vol53-issue3-fulltext-3338
- Fernández-Bravo, A., Fort-Gallifa, I., Ballester, F., et al. 2020. A case of *Aeromonas trota* in an immunocompromised patient with diarrhea. *Microorganisms*, 8: 399. doi: 10.3390/microorganisms8030399
- Food and Agriculture Organization (FAO). 2022. The state of world fisheries and aquaculture 2022. Towards blue transformation. FAO, Rome.
- Fridman, S., Sinai, T. & Zilberg, D. 2014. Efficacy of garlic-based treatments against monogenean parasites infecting the guppy (*Poecilia reticulata* (Peters)). *Veterinary Parasitology*, 203: 51-58. doi: 10.1016/j.vetpar.2014.02.002
- García-Magaña, L., Rodríguez-Santiago, M.A., Grano-Maldonado, M.I., et al. 2019. The effectiveness of sodium chloride and formalin in trichodiniasis of farmed freshwater tilapia *Oreochromis niloticus* (Linnaeus, 1758) cultured in southeastern Mexico. *Latin American Journal of Aquatic Research*, 47: 367-370. doi: 10.3856/vol47-issue1-fulltext-18
- Gonçalves-Pessoa, R.B., Marques, D.S., Lima, R.O., et al. 2020. Molecular characterization and evaluation of virulence traits of *Aeromonas* spp. isolated from the tambaqui fish (*Colossoma macropomum*). *Microbial Pathogenesis*, 147: 104273. doi: 10.1016/j.micpath.2020.104273
- Grano-Maldonado, M.I., Rodríguez-Santiago, M.A., García-Vargas, F., et al. 2018. An emerging infection caused by *Gyrodactylus cichlidarum* Paperna, 1968 (Monogenea: Gyrodactylidae) associated with massive mortality on farmed tilapia *Oreochromis niloticus* (L.) on the Mexican Pacific coast. *Latin American Journal of Aquatic Research*, 46: 961-968. doi: 10.3856/vol46-issue5-fulltext-9
- Haenen, O.L., Dong, H.T., Hoai, T.D., et al. 2023. Bacterial diseases of tilapia, their zoonotic potential and risk of antimicrobial resistance. *Reviews in Aquaculture*, 15: 154-185. doi: 10.1111/raq.12743
- Hernández-Vidal, U. 2024. Estrategias de alimentación y retos de la acuicultura tropical. *Tropical Aquaculture*, 2: 5740. doi: 10.19136/ta.a2n2.5740
- Hirazawa, N., Takano, R., Hagiwara, H., et al. 2010. The influence of different water temperatures on *Neobenedenia girellae* (Monogenea) infection, parasite growth, egg production and emerging second generation on amberjack *Seriola dumerili* (Carangidae) and the histopathological effect of this parasite on fish skin. *Aquaculture*, 299: 2-7. doi: 10.1016/j.aquaculture.2009.11.025
- Hoai, T.D. 2020. Reproductive strategies of parasitic flatworms (Platyhelminthes, Monogenea): the impact on parasite management in aquaculture. *Aquaculture*

- International, 28: 421-447. doi: 10.1007/s10499-019-00471-6
- Hutson, K.S., Brazenor, A.K., Vaughan, D.B., et al. 2018. Monogenean parasite cultures: current techniques and recent advances. *Advances in Parasitology*, 99: 61-91. doi: 10.1016/bs.apar.2018.01.002
- Jerônimo, G.T., Speck, G.M., Cechinel, M.M., et al. 2011. Seasonal variation on the ectoparasitic communities of Nile tilapia cultured in three regions in southern Brazil. *Brazilian Journal of Biology*, 71: 365-373. doi: 10.1590/S1519-69842011000300005
- Jiménez-García, I., Rojas-García, C.R. & Mendoza-Franco, E.F. 2020. Ecto-parasitic infection in Nile tilapia (*Oreochromis niloticus*) fry during male reversal in Veracruz, Mexico. *International Aquatic Research*, 12: 197-207. doi: 10.22034/IAR.2020.1898 558.1046
- Kačaniová, M., Terentjeva, M., Vukovic, N., et al. 2017. The antioxidant and antimicrobial activity of essential oils against *Pseudomonas* spp. isolated from fish. *Saudi Pharmaceutical Journal*, 25: 1108-1116. doi: 10.1016/j.jsps.2017.07.005
- Khallaf, M., El-Bahrawy, A., Awad, A., et al. 2020. Prevalence and histopathological studies of *Trichodina* spp. infecting *Oreochromis niloticus* in Behera Governorate, Egypt. *Journal of Current Veterinary Research*, 2: 1-7. doi: 10.21608/JCVR.2020.90213
- Li, M., Sun, Z., Wang, C., et al. 2016. Ultrastructural study of *Apiosoma piscicola* Blanchard, 1885 (Subclass: Peritrichia) on *Tachysurus fulvidraco* from China. *Journal of Parasitic Diseases*, 40: 1429-1434. doi: 10.1007/s12639-015-0708-7
- Lim, S.Y., Ooi, A.L. & Wong, W.L. 2016. Gill monogeneans of Nile tilapia (*Oreochromis niloticus*) and red hybrid tilapia (*Oreochromis* spp.) from the wild and fish farms in Perak, Malaysia: infection dynamics and spatial distribution. *SpringerPlus*, 5: 1609. doi: 10.1186/s40064-016-3266
- Lima-Boijink, C., da Cunha-Miranda, W.S., Chagas, E.C., et al. 2015. Anthelmintic activity of eugenol in tambaquis with monogenean gill infection. *Aquaculture*, 438: 138-140. doi: 10.1016/j.aquaculture.2015.01.014
- Loch, T.P. & Faisal, M. 2015. Emerging flavobacterial infections in fish: a review. *Journal of Advanced Research*, 6: 283-300. doi: 10.1016/j.jare.2014.10.009
- Lom, J. 1958. A contribution to the systematic and morphology of endoparasitic trichodinids from amphibians, with a proposal of uniform specific characteristics. *Journal of Parasitology*, 5: 251-263. doi: 10.1111/j.1550-7408.1958.tb02563.x
- Lom, J. & Dykova, I. 1992. *Protozoan parasites of fishes*. Elsevier, Amsterdam.
- López-Ceseña, J.Á.G., Rodríguez-Montes de Oca, G.A., Hernández, A.B., et al. 2024. Tratamiento para el control de *Gyrodactylus* sp. y *Cichlidogyrus* sp. asociados con mortalidad en tilapia (*Oreochromis niloticus*). *Revista Ciencia del Mar, UAS*, 1: 30-58.
- Maciel, P.O., García, F., Chagas, E.C., et al. 2018. Trichodinidae in commercial fish in South America. *Reviews in Fish Biology and Fisheries*, 28: 33-56. doi: 10.1007/s11160-017-9490-1
- Madsen, H.C., Buchmann, K. & Møllergaard, S. 2000. *Trichodina* sp. (Ciliophora: Peritrichida) in eel *Anguilla anguilla* in recirculation systems in Denmark: host-parasite relations. *Diseases of Aquatic Organisms*, 42: 149-152. doi: 10.3354/dao042149
- Mandira, S., Bandyopadhyay, P.K. & Göçmen, B.A.Y. 2017. First record of ectoparasitic ciliates, of genus *Trichodina* (Ciliophora: Trichodinidae) parasiting cultured oranda goldfish (*Carassius auratus auratus* L.) in India. *Zootaxa*, 4319: 128-142. doi: 10.11646/zootaxa.4319.1.6
- Mastelini, V. & Neto, M.M. 2024. Application for analyzing water quality for tilapia fish farming in the net tank. *ARACE*, 6: 048. doi: 10.56238/arev6n2-048
- Mizuno, S., Urawa, S., Miyamoto, M., et al. 2016. The epidemiology of the trichodinid ciliate on hatchery-reared and wild salmonid fish in Hokkaido. *Fish Pathology*, 51: 199-209. doi: 10.3147/jsfp.51.199
- Naas, C., Muhammad, H., Kloas, W., et al. 2024. Sodium chloride (NaCl) as a treatment against trichodiniasis for pike perch (*Sander lucioperca*) in recirculating aquaculture systems. *Aquaculture International*, 32: 4449-4464. doi: 10.1007/s10499-023-01383-2
- Oktami, E.T., Mulyasari, G., Yuliarso, M.Z., et al. 2024. Analisis sistem agribisnis budidaya ikan nila agribusiness system analysis in tilapia cultivation. *Mahatani*, 7: 258-273. doi: 10.52434/mja.v7i2.41850
- Oliveira-Hashimoto, G.S., Neto, F.M., Ruiz, M.L., et al. 2016. Essential oils of *Lippia sidoides* and *Mentha piperita* against monogenean parasites and their influence on the hematology of Nile tilapia. *Aquaculture*, 450: 182-186. doi: 10.1016/j.aquaculture.2015.07.029
- Ortega, C., García, I., Irgang, R., et al. 2018. First identification and characterization of *Streptococcus iniae* obtained from tilapia (*Oreochromis aureus*)

- farmed in Mexico. *Journal of Fish Diseases*, 41: 773-782. doi: 10.1111/jfd.12775
- Palmeira, B.V., da Silveira-Neto, O.J., Taveira, R.Z., et al. 2024. Good agricultural practices in the production of Nile tilapia (*Oreochromis niloticus*) in a simple recirculation system in urbanized areas. In: *Roots of the future: Innovations in agricultural and biological sciences*. Seven Editora Academica, Paraná.
- Pantoja, M.F.W., Neves, L., Dias, M., et al. 2012. Protozoan and metazoan parasites of Nile tilapia *Oreochromis niloticus* cultured in Brazil. *Revista MVZ Córdoba*, 17: 2812-2819. doi: 10.21897/rmvz.248
- Paredes-Trujillo, A., Velázquez-Abunader, I., Papiol, V., et al. 2021. Negative effects of ectoparasite burdens on the condition factor from farmed tilapia *Oreochromis niloticus* in the Yucatan, Mexico. *Veterinary Parasitology*, 292: 109393. doi: 10.1016/j.vetpar.2021.109393
- Paredes-Trujillo, A., Velázquez-Abunader, I., Torres-Irineo, E., et al. 2016. Geographical distribution of protozoan and metazoan parasites of farmed Nile tilapia *Oreochromis niloticus* (L.) (Perciformes: Cichlidae) in Yucatán, Mexico. *Parasite and Vectors*, 9: 66. doi: 10.1186/s13071-016-1332-9
- Paull, S.H., Raffel, T.R., LaFonte, B.E., et al. 2015. How temperature shifts affect parasite production: testing the roles of thermal stress and acclimation. *Functional Ecology*, 29: 941-950. doi: 10.1111/1365-2435.12401
- Pereira, C., Duarte, J., Costa, P., et al. 2022. Bacteriophages in the control of *Aeromonas* sp. in aquaculture systems: an integrative view. *Antibiotics*, 11: 163. doi: 10.3390/antibiotics11020163
- Phuoc, N.N., Linh, N.T.H., Crestani, C., et al. 2021. Effect of strain and environmental conditions on the virulence of *Streptococcus agalactiae* (Group B *Streptococcus*; GBS) in red tilapia (*Oreochromis* sp.). *Aquaculture*, 534: 736256. doi: 10.1016/j.aquaculture.2020.736256
- Puicón, V., López, A. & Murrieta, G. 2023. Ectoparásitos en branquias de tilapias adultas (*Oreochromis niloticus*) del sector Bello Horizonte de la Banda de Shilcayo, San Martín, Perú. *Revista de Investigaciones Veterinarias del Perú*, 34: e24596. doi: 10.15381/rirep.v34i1.24596
- Rivas-Beltrán, M., Islas-Ortega, A.G., Contreras-Medina, R., et al. 2023. Ciliate diversity in a backyard fish farm from Zimatlán de Álvarez, Oaxaca, Mexico: an island of aquatic microscopic biodiversity from a semi-urban area. *Latin American Journal of Aquatic Research*, 51: 658-670. doi: 10.3856/vol51-issue5-full text-3065
- Rodríguez-Santiago, M.A., Álvarez-Borrego, J., Fajer-Ávila, E.J., et al. 2021. Invariant correlation with species-specific composite filters for the recognition of trichodinids (Ciliophora: Peritrichida) parasitizing *Oreochromis niloticus* (Linnaeus, 1758) based on morphology. *Neotropical Helminthology*, 15: 179-191. doi: 10.24039/rnh20211521223
- Rodríguez-Santiago, M.A., García-Magaña, L., Grano-Maldonado, M.I., et al. 2019. Primer registro de *Trichodina centrostrigeata* Basson, Van As & Paperna, 1983 (Ciliophora: Trichodinidae) de *Oreochromis niloticus* (Linnaeus, 1758) cultivado en el sureste de México. *Latin American Journal of Aquatic Research*, 47: 367-370. doi: 10.3856/vol47-issue2-full text-18
- Sandoval-Gío, J.J., Rodríguez-Canul, R.P., Vidal-Martínez, V.M., et al. 2019. Formalin toxicity to *Oreochromis niloticus*; its effectiveness against *Cichlidogyrus* spp. and host stress response. *Latin American Journal of Aquatic Research*, 47: 34-41. doi: 10.3856/vol47-issue1-full text-5
- Shinn, A.P., Avenant-Oldewage, A., Bondad-Reantaso, M.G., et al. 2023. A global review of problematic and pathogenic parasites of farmed tilapia. *Reviews in Aquaculture*, 15: 92-153. doi: 10.1111/raq.12742
- Soler-Jiménez, L.C., Paredes-Trujillo, A.I. & Vidal-Martínez, V.M. 2017. Helminth parasites of finfish commercial aquaculture in Latin America. *Journal of Helminthology*, 91: 110-136. doi: 10.1017/S0022149X16000833
- Soto-Rodríguez, S.A., Marrujo-López, F.I., Aguilar-Rendon, K.G., et al. 2024. Pathogenic bacteria prevalence in cultured Nile tilapia in southwest Mexico: A real-time PCR analysis. *Journal of Fish Diseases*, 47: e13921. doi: 10.1111/jfd.13921
- Sousa-Filho, I.P., Moares, R.S., Saturnino, K.C., et al. 2021. First record of *Trichodina heterodontata* (Ciliophora: Trichodinidae) in banded knifefish *Gymnotus carapo* (Gymnotidae) cultured in Brazil. *Brazilian Journal of Biology*, 82: e240840. doi: 10.1590/1519-6984.240840
- Steckert, L.D., Cardoso, L., Jerônimo, G.T., et al. 2018. Investigation of farmed Nile tilapia health through histopathology. *Aquaculture*, 486: 161-169. doi: 10.1016/j.aquaculture.2017.12.021
- Suliman, E.A.M. & Al-Harbi, A.H. 2016. Prevalence and seasonal variation of ectoparasites in cultured Nile tilapia *Oreochromis niloticus* in Saudi Arabia. *Journal of Parasitic Diseases*, 40: 1487-1493. doi: 10.1007/s12639-015-0717-6
- Swingle, J.S., Daly, B. & Hetrick, J. 2013. Temperature effects on larval survival, larval period, and health of

- hatchery-reared red king crab, *Paralithodes camtschaticus*. *Aquaculture*, 384: 13-18. doi: 10.1016/j.aquaculture.2012.12.015
- Tancredo, K.R., Marchiori, N.D.C., Pereira, S.A., et al. 2019. Toxicity of formalin for fingerlings of *Cyprinus carpio* var. koi and *in vitro* efficacy against *Dactylogyrus minutus* Kulwièc, 1927 (Monogenea: Dactylogyridae). *Journal of Parasitic Diseases*, 43: 46-53. doi: 10.1007/s12639-018-1056-1
- Tang, F.H., Zhao, J. & Warren, A. 2013. Phylogenetic analyses of trichodinids (Ciliophora, Oligohymenophora) inferred from 18S rRNA gene sequence data. *Current Microbiology*, 66: 306-313. doi: 10.1007/s00284-012-0274-5
- Tavares-Dias, M. 2021. Toxicity, physiological, histopathological and antiparasitic effects of the formalin, a chemotherapeutic of fish aquaculture. *Aquaculture Research*, 52: 1803-1823. doi: 10.1111/are.15069
- Turgut, E. 2012. Influence of temperature and parasite intensity on egg production and hatching of the monogenean *Dactylogyrus extensus*. *Israeli Journal of Aquaculture - Bamidgah*, 64. doi: 10.46989/001c.20625
- Valladão, G.M.R., Alves, L.D.O. & Pilarski, F. 2016. Trichodiniasis in the Nile tilapia hatcheries: diagnosis, parasite: host-stage relationship and treatment. *Aquaculture*, 451: 444-450. doi: 10.1016/j.aquaculture.2015.09.030
- Van, K., Minh, K., Duc, V., et al. 2021. Effects of dermogard product on treatment of parasites infected in common carp (*Cyprinus carpio*). *Concepts of Dairy & Veterinary Sciences*, 4: 454-458. doi: 10.32474/CDVS.2021.04.000195
- Wahli, T. & Madsen, L. 2018. Flavobacteria, a never-ending threat for fish: a review. *Current Clinical Microbiology Reports*, 5: 26-37. doi: 10.1007/s40588-018-0086-x
- Wellborn, T.L. 1967. Trichodina (Ciliata: Urceolariidae) of freshwater fishes of the southeastern United States. *Journal of Protozoology*, 14: 399-412. doi: 10.1111/j.1550-7408.1967.tb02017.x
- Wiklund, T. 2016. *Pseudomonas anguilliseptica* infection as a threat to wild and farmed fish in the Baltic Sea. *Microbiology Australia*, 37: 135-136. doi: 10.1071/MA16046
- Young, E.J., Bannister, J., Buller, N.B., et al. 2020. *Streptococcus iniae* associated mass marine fish kill off western Australia. *Diseases of Aquatic Organisms*, 142: 197-201. doi: 10.3354/dao03545
- Yusni, E. & Rambe, N. 2019. Identification of ectoparasites in fry tilapia (*Oreochromis niloticus*) in aquaculture pond. *IOP Conference Series: Earth and Environmental Science*, 260: 012110. doi: 10.1088/1755-1315/260/1/012110
- Zago, A.C., Franceschini, L., Garcia, F., et al. 2014. Ectoparasites of Nile tilapia (*Oreochromis niloticus*) in cage farming in a hydroelectric reservoir in Brazil. *Revista Brasileira de Parasitologia Veterinária*, 23: 171-178. doi: 10.1590/S1984-29612014041
- Zhang, X.P., Li, W.X., Ai, T.S., et al. 2014. The efficacy of four common anthelmintic drugs and traditional Chinese medicinal plant extracts to control *Dactylogyrus vastator* (Monogenea). *Aquaculture*, 420: 302-307. doi: 10.1016/j.aquaculture.2013.09.022
- Zhang, S., Zhi, T., Xu, X., et al. 2019. Monogenean fauna of alien tilapias (Cichlidae) in south China. *Parasite*, 26: 4. doi: 10.1051/parasito/2019003
- Zorin, B., Gibson-Kueh, S. & Zilberg, D. 2019. A novel treatment against the monogenean parasite, *Gyrodactylus turnbulii*, infecting guppies (*Poecilia reticulata*), using a plant-based commercial insecticide, Timor C. *Aquaculture*, 501: 313-318. doi: 10.1016/j.aquaculture.2018.11.038

Received: March 31, 2025; Accepted: December 15, 2025